

Endodontic Management of Three-Rooted Maxillary First Premolar- A Case Report

Hena Rahman¹, Abdul Aziz², Ramesh Chandra³, Shailja Singh¹,
Abid Amin Lanker²

¹(Associate Professor, Department of Conservative Dentistry and Endodontics, Career PG Institute of Dental Science and Hospital, Lucknow, India)

²(Ex-PG Student, Department of Conservative Dentistry and Endodontics, Career PG Institute of Dental Science and Hospital, Lucknow, India)

³(Professor, Department of Conservative Dentistry and Endodontics, Career PG Institute of Dental Science and Hospital, Lucknow, India)

Abstract: The maxillary first premolars usually have two roots located buccally and palatally, but occasionally they have an additional root located distobuccally requiring special attention when root canal treatment is being considered. The additional root is regarded as a normal racial and morphological variation rather than as an abnormality. A correct clinical and radiographic diagnosis based on knowledge of root canal anatomy and critical interpretation of radiographs is necessary for a safer and successful endodontic treatment of these teeth. Failure of root canal treatment can occur due to missed roots/canals and often diagnosed when patient experiences continuous post-operative pain and discomfort. The occurrence of three canals with separate foramina in both first and second premolars is shown to be in extremely low percentages and has been documented as practically non-existent in Asian populations. This article describes a case report of endodontic management of unilateral three-rooted maxillary first premolar.

Keywords: Maxillary first premolar, anatomic variation, root canal treatment.

I. Introduction

The key to success of endodontic treatment is thorough debridement and complete obturation of the entire root canal system, while the thorough knowledge of root canal space anatomy is a basic prerequisite for long term success of endodontic treatment [1], especially in cases of complex root canal anatomy, where extra root canals are expected [2]. Studies have reported that complex root canal anatomy or anatomic variations can occur in all groups of teeth [3,4].

Low rate of incidence of three canals in maxillary premolars have been reported till date. In case of the first premolar, three root canals were found at a frequency of 0.5% to 6% [4-6], whereas in the second premolar the incidence was from 0.3% to 2% [7-8]. In past studies have reported that the presence or absence of a third root canal is influenced by genetic factors and that three rooted premolars are more common in Caucasian populations and virtually non-existent in Asian populations [9,10].

According to literature reviews, we find a divergence of opinion concerning the root and canal morphology of the first maxillary premolar. The incidence of one root varied from 22.0 to 49.4%; two roots, 50.6 to 72%; and three roots, 0 to 6% [5,6,7,8]. Studies performed by Carns and Skid (1973), Green (1973) and Pineda and Kuttler (1972), reported that in most instances the first maxillary premolars have two canals (from 73.3 to 92%), although teeth with one or three root canals do often exist (from 8 to 26.2% and from 0 to 6%, respectively) [5,11,12].

Routine preoperative radiography gives a two dimensional view of a three dimensional object but precise interpretation can reveal fine anatomic details that suggest the presence of extra roots or canals. An extra canal should be suspected, whenever there is an abrupt straightening or loss of radiolucent canal in the pulp cavity [13]. In case of maxillary premolar whenever the mesio-distal width of the root image is equal to or greater than the mesio-distal width of the crown, the tooth most likely has three roots [14]. Now a days, operating microscope and Cone Beam Computed Tomography (CBCT) are advancements which aid in diagnosis and treatment planning of cases with complex root canal anatomy.

The objective of this article is to report a rare clinical case and discuss the treatment approach for a rare occurrence of three rooted maxillary first premolars.

II. Case Report

A 35-year-old woman with a noncontributory medical history was reported to the department of conservative dentistry and endodontics with chief complain of pain and food lodgment in upper right posterior

region for last one month. Clinical examination showed a large coronal carious lesion in relation to tooth # 16 and a occluso-proximal lesion in relation to tooth # 14 with no evidence of swelling and sinus tract. Vitality test with heated guttapercha stick, and electric pulp tester revealed severe, rapid, lingering pain from the maxillary first premolar, while first molar elicits no response. Pre-operative periapical radiograph (figure 1(a)) revealed deep caries involving the pulp for both the tooth and widening of periodontal ligament space in relation to 16, a periapical pathology was seen in relation to tooth # 16. In the middle-third of the root of tooth # 14 a greater than normal mesio-distal width associated with complex root morphology was observed. The periapical radiograph of the contralateral side had normal anatomical conformation. Based on clinical and radiological evidence it was diagnosed as acute irreversible pulpitis for maxillary first premolar and chronic irreversible pulpitis for maxillary first molar. Root canal treatment was planned for first premolar and non-surgical treatment approach was preferred for maxillary first molar.

Informed consent was taken from the patient. The access cavity preparation was done under proper rubber dam isolation under local anesthesia (figure 1(b)). One large buccal and one palatal canal orifice were located using an endodontic explorer at the first instant. The access cavity was then slightly modified and extension of the buccal orifice was carried out using a slow speed round bur (DentsplyMaillefer). By exploring the extended buccal orifice with an endodontic explorer using a DG16 explorer, the exact location of the mesio-buccal and disto-buccal canals was confirmed. The root canals were explored with k-flex file ISO #15 (DentsplyMaillefer) and working length determination was performed with elements diagnostic apex locator (Sybronendo, USA,) and confirmed radiographically (figure 1(c)).

The remaining root canal system was prepared with K-files with copious irrigation using 1.5% sodium hypochloride solution. The master apical files in buccal canals and palatal canal were ISO size 35 and 40 respectively. The canals were dried with paper points and obturated by laterally condensed guttapercha (Roeko, Germany) and AH-Plus (Densply, Germany) root canal sealer. A final radiograph was taken to confirm the quality of the obturation (figure 1(d)). Permanent restoration was done at the next appointment.

Similarly, access cavity preparation was done for maxillary first molar and canals were enlarged and prepared. Intracanal medicament calcium hydroxide mixed with saline was introduced within the canal and temporary filling was done coronally. Patient was kept on recall process to assess healing of periapical area.

III. Discussion

Normal tooth anatomy is easy to understand but variations make it interesting and complex. The possible anatomic configurations of maxillary premolars are well documented in the literature. Good quality preoperative radiographs with different angulations and their careful examination are essential for the detection of additional root and root canals [15-17]. If a radiograph shows a sudden narrowing or even a disappearing pulp space, there may be possibility that the canal diverges at that point into two parts that may either remain separate or merge before reaching the apex [18]. Generally, two orifices are present one buccal and one palatal but if an eccentric orifice found, at least one more canal is present and should be searched for on the opposite side [8]. Moreover, if the dentinal map is not in straight line buccopalatally and seems to be either triangular in shape or too large in a mesiodistal plane, an extra root or root canal should be suspected [23].

While treating unusual tooth anatomy e.g., three rooted maxillary premolars, good illumination and magnification can make treatment easier. With the aid of an operating microscope it is possible to locate all the root canal orifices clinically [24] and to confirm it three dimensionally advancement of CBCT is proved as a bane in dentistry.

This article has described the clinical management of first premolar with three canals and three separate roots. Detection of three-canalled maxillary premolar can often be difficult on routine preoperative radiographs. The root canal configuration of three- rooted maxillary premolars resembles that of a miniature three-canalled maxillary molar; the canals being classified as the mesio-buccal, disto-buccal and palatal canals. Three rooted configuration can be sometimes seen on preoperative radiographs. In present case, diagnostic periapical radiography revealed a greater mesio-distal width at middle third of root of maxillary first premolar, that's why a third root was expected. It was difficult to find canal accesses because the buccal orifices were too close to each other. Sieraski et al., advocated a "T" shape modification of maxillary first premolar extending mesio-distally the buccal aspect of the usual outline form which allows proper access to each of the two buccal canals [14].

IV. Figure

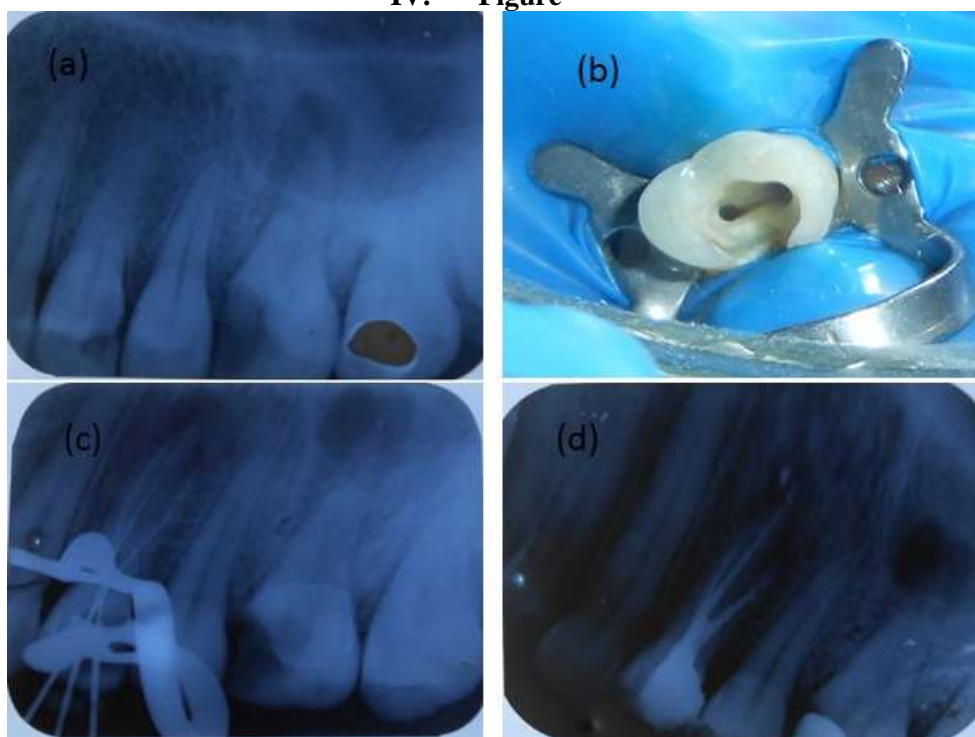


Figure 1 (a) showing pre-operative radiograph, (b) access cavity preparation, (c) working length determination and (d) obturation of three-rooted maxillary right first premolar.

V. Conclusion

This rare case report presents yet another depiction of the anatomical variation of maxillary first premolar with three roots and root canals which has reported incidence rate of 0-6% only. The possibility of presence of multiple canals and additional roots in different cases should be carefully explored and treated. Use of advanced imaging techniques have improved success rate of root canal treatment in such cases.

References

- [1] Rodig T, Hulsmann M. Diagnosis and root canal treatment of a mandibular second premolar with three root canals. *IntEndod J* 2003;36:912-9.
- [2] Sikri VK, Sikri P. Mandibular premolars: aberrations in pulp space morphology. *Indian J Dent Res* 1994;5:9-14.
- [3] Cohen S, Burns RC. *Pathways of the Pulp*. 5th ed. St. Louis: Mosby; 2002. pp. 173-228.
- [4] Vertucci FJ. Root canal morphology and its relationship to endodontic procedures. *Endod Topics* 2005;10:3-29.
- [5] Carns EJ, Skidmore AE. Configuration and deviations of root canals of maxillary first premolars. *Oral Surg* 1973;36: 880-886.
- [6] Kartal N, Ozelik B, Cimilli H. Root canal morphology of maxillary premolars. *J Endod* 1998;24: 417-419
- [7] Loh HS. Root morphology of the maxillary first premolar in Singaporeans. *Aust Dent J* 1998;43: 339-402
- [8] Vertucci FJ, Gegauff A. Root canal morphology of the maxillary first premolars. *J Am Dent Assoc* 1979;99: 194-198
- [9] Nallapati S. Three-canal maxillary premolar teeth: a common clinical reality. *EndodPrac* 2003;6:22-8.
- [10] Cardinali F, Cerutti F, Tosco E, Cerutti A. Preoperative diagnosis of a third root canal in first and second maxillary premolars: A challenge for the clinician. *ENDO* 2009;3:51-7.
- [11] Green D. Double canals in single roots. *Oral Surg* 1973;35: 690-691.
- [12] Pineda F, Kuttler Y. Mesiodistal and buccolinqualroentgenographic investigation of 7,275 root canals. *Oral Surg* 1972;33: 101-110.
- [13] Soares JA, Leonardo RT. Root canal treatment of three rooted maxillary first and second premolars- a case report. *IntEndod J* 2003;36:705-710.
- [14] Sieraski SM, Taylor GN, Kohn RA. Identification and endodontic management of three canalled maxillary premolars. *J Endod* 1989;15:29-32.
- [15] Slowly RR. Radiographic aids in the detection of extra canals. *Oral Surg, Oral Med Oral Pathol* 1974;37:762-772.
- [16] Slowly RR. Root canal anatomy- road map to successful endodontics. *Dent Clin North Am* 1979;23:555-573.
- [17] Javidi M, Zarei M, Vatanpour M. Endodontic treatment of a radicular maxillary premolar: a case report. *J Oral Sci* 2008;50:99-102.
- [18] Vertucci FJ. Root morphology of mandibular premolars. *J Am Dent Assoc* 1978;97:47-50.
- [19] Al-Fouzan KS. The microscopic diagnosis and treatment of a mandibular second premolar with four canals. *IntEndod J* 2001;34:406-410.
- [20] Carr GB. Microscopes in endodontics. *J Calif Dent Assoc* 1992;20:55-61.